




Contents lists available at ScienceDirect

European Journal of Obstetrics & Gynecology and Reproductive Biology

journal homepage: www.journals.elsevier.com/european-journal-of-obstetrics-and-gynecology-and-reproductive-biology

Expert Opinion



European consensus statement on expert colposcopy

A.E. McGee^{a,*}, T. Alibegashvili^b, K. Elfgrén^c, B. Frey^d, M. Grigore^e, A. Heinonen^f, R. Jach^g, K. Jariene^h, V. Kesicⁱ, V. Küppers^j, M. Kyrgiou^k, S. Leeson^{l,m}, J. Louwersⁿ, M. Mazurec^{o,p}, J. Mergui^q, A. Pedro^r, A. Šavrova^s, E. Siegler^t, U. Tabuica^u, D. Trojnaraska^g, M. Trzeszcz^{o,p}, R. Turyna^{v,w,x}, N. Volodko^y, M.E. Cruickshank^a, on Behalf of the European Federation for Colposcopy and Pathology of the Lower Genital Tract (EFC) and the European Society of Gynaecological Oncology (ESGO)

^a Aberdeen Centre for Women's Health Research (ACWHR), University of Aberdeen, UK^b Department of Gynaecology, Georgian National Screening Center, Tbilisi, Georgia^c Karolinska Institutet, Stockholm, Sweden^d Frauenklinik Baselland, Switzerland^e Department of Obstetrics and Gynaecology, University of Medicine and Pharmacy "Grigore T. Popa" Iasi, Romania^f Department of Obstetrics and Gynecology, University of Helsinki, and Helsinki University Hospital^g Institute of Nursing and Obstetrics, Faculty of Health Sciences, Jagiellonian University Medical College, Krakow, Poland^h Department of Obstetrics and Gynecology, Medical Academy, Lithuanian University of Health Sciences, Kaunas, Lithuaniaⁱ Faculty of Medicine, University of Belgrade, Clinic of Obstetrics and Gynaecology, Clinical Center of Serbia, Belgrade, Serbia^j Frauenheilkunde & Geburtshilfe, Zytologisches Labor, Dysplasie-Sprechstunde, Düsseldorf, Germany^k IRDB, MDR & Surgery and Cancer, Faculty of Medicine, Imperial College London, UK^l West London Gynaecological Cancer Centre, Imperial College NHS Trust, UK^m Department of Obstetrics and Gynaecology, Ysbyty Gwynedd, Betsi Cadwaladr University Health Board, Wales, UKⁿ Diakonessenhuis, Bosboomstraat 1, 3582 KE, Utrecht, the Netherlands^o Corfamed Woman's Health Center, Kluczborska, Wroclaw, Poland^p Department of Pathology and Clinical Cytology, University Hospital in Wroclaw, Poland^q Department of Gynecological and Breast Surgery and Oncology, Pitié-Salpêtrière, Assistance Publique des Hôpitaux de Paris (AP-HP), University Hospital, Paris, France^r Department of Obstetrics and Gynaecology, CUF Sintra Hospital, Sintra, Portugal^s Gynaecology Centre, North Estonia Medical Centre, Estonia^t The Israeli Society of Colposcopy and Cervical and Vulvar Pathology, Peretz Berenstein St, Haifa, Israel^u Department of Obstetrics and Gynaecology, State University of Medicine and Pharmacy, Referral Center of Colposcopy, Chisinau, Moldova^v Institute for the Care of Mother and Child, Prague 4, Czech Republic^w Third Faculty of Medicine, Charles University, Prague 10, Czech Republic^x Institute of Postgraduate Education in Health Care - IPVZ, Prague 10, Czech Republic^y Department of Oncology and Radiology, Danylo Halitsky Lviv national medical university, Lviv, Ukraine

ARTICLE INFO

Keywords:

Colposcopy
European guideline
Cervix
Screening
Cancer

ABSTRACT

Background: Following the publication of the European consensus statement on standards for essential colposcopy in 2020, the need for standards relating to more complex and challenging colposcopy practice was recognised. These standards relate to colposcopy undertaken in patients identified through cervical screening and tertiary referrals from colposcopists who undertake standard colposcopy only.

This set of recommendations provides a review of the current literature and agreement on care for recognised complex cases. With good uptake of human papillomavirus (HPV) immunisation, we anticipate a marked reduction in cervical disease over the next decade. Still, the expert colposcopist will continue to be vital in managing complex cases, including previous cervical intraepithelial neoplasia (CIN)/complex screening histories and multi-zonal disease.

Aims: To provide expert guidance on complex colposcopy cases through published evidence and expert consensus.

* Corresponding author at: Aberdeen Centre for Women's Health Research, Aberdeen Maternity Hospital, Cornhill Road, Aberdeen AB25 2ZL, Scotland, United Kingdom.

E-mail address: alice.mcgee@abdn.ac.uk (A.E. McGee).

<https://doi.org/10.1016/j.ejogrb.2023.08.369>

Received 25 June 2023; Received in revised form 7 August 2023; Accepted 18 August 2023

Available online 31 August 2023

0301-2115/© 2023 The Author(s). Published by Elsevier B.V. This is an open access article under the CC BY license (<http://creativecommons.org/licenses/by/4.0/>).

Material & methods: Members of the EFC and ESGO formed a working group to identify topics considered to be the remit of the expert rather than the standard colposcopy service. These were presented at the EFC satellite meeting, Helsinki 2021, for broader discussion and finalisation of the topics.

Results & discussion: The agreed standards included colposcopy in pregnancy and post-menopause, investigation and management of glandular abnormalities, persistent high-risk HPV+ with normal/low-grade cytology, colposcopy management of type 3 transformation zones (TZ), high-grade cytology and normal colposcopy, colposcopy adjuncts, follow-up after treatment with CIN next to TZ margins and follow-up after treatment with CIN with persistent HPV+, and more. These standards are under review to create a final paper of consensus standards for dissemination to all EFC and ESGO members.

Key recommendations

- Women with an abnormal screening test in pregnancy have the same referral criteria as nonpregnant. [Grade ✓]
- Type 3 transformation zone (TZ) is more common in postmenopausal women, and the expert colposcopist should be able to offer a type 3 excision. [Grade ✓]
- Colposcopy +/- endocervical sampling is the initial management for all atypical glandular cells (AGC) cytology subcategories and adenocarcinoma *in situ* (AIS) for nonpregnant women, except atypical endometrial cells. [Grade ✓]
- Women with hr-HPV persistence will either become HPV negative or may develop HSIL/CIN2+ within six years, even with intensive clinical follow-up. However, the overall prevalence of HSIL is low. [Grade B]
- Management of women with a type 3 TZ depends on the referral HRHPV status, cytology, and the results of any biopsies at colposcopy and multi-disciplinary team review may aid management. [Grade ✓]
- Women with high-grade cytology and normal colposcopy (negative histology) should have close surveillance. [Grade ✓]
- Any excision or hysterectomy for a woman with a persistent positive HRHPV test will require cytological/colposcopic abnormality or CIN on biopsy to avoid overtreatment. [Grade ✓]
- HRHPV testing after treatment of CIN 2+ is recommended for early detection of disease recurrence or progression. [Grade C]
- Women who are chronically immunosuppressed, unrelated to HIV, should be monitored as per the national guidelines for the general population. Any abnormal result should be managed per the guidance for women with HIV. [Grade ✓]
- Adjunctive technology may be used as a diagnostic aid in colposcopy, but treatment decisions should not be based only on adjunctive technology. [Grade A]

Background and scope

Following the publication of the European consensus statement on standards for essential colposcopy in 2020 [1], the need for standards relating to more challenging colposcopy practice was recognised. These standards relate to colposcopy undertaken in patients identified through cervical screening and tertiary referrals from colposcopists who undertake standard colposcopy only.

This guideline summarises the evidence regarding managing challenging cases in colposcopy practice. The guideline provides guidance about the different care options available. These should be considered in conjunction with the wishes of the woman, as part of shared and informed decision-making.

Within this guideline, we use the terms woman and women's health. However, it is important to acknowledge that it is not only people who identify as women for whom it is necessary to access care. Obstetric and gynaecology services and care delivery must therefore be appropriate, inclusive, and sensitive to the needs of those individuals whose gender identity does not align with the sex they were assigned at birth.

Introduction

Our understanding of the expert colposcopist varies across Europe; in some countries, for example, the United Kingdom (UK) or Germany, all colposcopists train to a specialist level and are expected to provide expert advice and management. In Poland, the colposcopist is trained by PSCCP in two tiers: a certified colposcopist or a certified expert colposcopist [2,3].

Like the consensus on standards for essential colposcopy, these recommendations do not cover every eventuality but provide a review of the current literature and expert agreement on care for complex cases. With increasing uptake of human papillomavirus (HPV) immunisation, we anticipate a reduction in precancer of the cervix and lower genital tract over the next decade. However, the expert colposcopist will continue to be critical to managing older women, those with chronic immunosuppression, and those with a previous histological diagnosis of HSIL. Those with multi-zonal disease are challenging not only to colposcopists but also to other specialists. Guidance on vaginal and vulval disease has been developed by the European Federation for Colposcopy (EFC) and the European Society of Gynaecological Oncology (ESGO) [4,5].

Members of the EFC and ESGO formed a working group to identify topics considered as the remit of the expert rather than the standard colposcopist. These were presented at the EFC satellite meeting, Helsinki 2021, for broader discussion and finalisation of the topics. The working group developed draft standards which members of the EFC and ESGO reviewed as an iterative process. This guideline aims to provide expert guidance supported by published evidence to review emerging evidence and update practice.

Assessment of evidence

This guideline was developed in accordance with the standard methodology for producing Royal College of Obstetricians and Gynaecologists (RCOG) Green-top Guidelines. Where possible, recommendations are based on the available evidence. Where there is no published evidence, recommendations have been annotated as 'good practice points.' Further information about how the assessment of evidence and the grading of recommendations was carried out can be found in Appendix 1.

Colposcopy in pregnancy

The colposcopy referral criteria for an abnormal cervical screening test during pregnancy remain the same as for non-pregnant women to exclude invasive carcinoma and reassure the pregnant woman promptly. In pregnancy, a high-grade squamous intraepithelial lesion (HSIL) has an estimated risk of progression to invasive carcinoma of <2 % [6,7]. There is also an expectation of regression of some HSIL, which does not appear to depend on the mode of delivery [8].

The management of pregnant patients should be individualised, considering HPV status, the grade of cytology, gestation, and any other recognised risk factors. Conservative management of histological HSIL during pregnancy is acceptable but requires surveillance by an

experienced colposcopist. This includes an examination of the whole transformation zone (TZ) in pregnancy and recognising pregnancy changes, such as active metaplasia with dense aceto-whitening, enhanced capillary vessel patterns and decidual change, including decidual polyps, which requires experience.

Grade of recommendation: ✓

Colposcopy-directed biopsies in pregnant patients appear safe but are only necessary when invasion is suspected. The biopsy should be large enough for reliable histological assessment; punch biopsies may not exclude invasive disease. If excisional treatment is considered, the risk of complications depends on the type of procedure (cold knife conization, laser conization or Large Loop Excision of Transformation Zone (LLETZ)) and the timing in relation to gestation. Recent observational studies of conization at 15–19 weeks' gestation did not identify high rates of severe complications (haemorrhage, miscarriage, or premature delivery [8–10]). However, these should only be done with therapeutic, rather than diagnostic, intent following biopsy-confirmed HSIL. We recommend the establishment of a European registry of women diagnosed with HSIL during pregnancy and their outcomes.

Grade of recommendation: C

Summary of recommendations

- Women with an abnormal screening test in pregnancy have the same referral criteria as nonpregnant.
- Conservative management of HSIL (high-grade CIN: CIN2, CIN3 or HSIL unspecified) during pregnancy is acceptable but requires surveillance by an experienced colposcopist.
- Colposcopy-directed biopsies are only necessary when invasion is suspected.

Colposcopy for postmenopausal women

The incidence of high-risk HPV (HR-HPV) positivity and abnormal cytology is low in postmenopausal women with previous normal results [11]. Colposcopy for postmenopausal women can be challenging; many postmenopausal women will have a type 3 TZ, and the effect of low oestrogen levels on cervical epithelium may mimic low-grade cytological changes [12]. Shrinkage of cervical stroma retracts the SCJ into the endocervical canal and narrows the external cervical os. Epithelial thinning results in visibility of capillary vessel networks, and the acetic acid application is not always effective in revealing disease.

The lack of intracellular glycogen results in partial iodine uptake, ranging from a variegated or patchy appearance to a complete lack of uptake with pale yellow staining. In postmenopausal women, cervical disease is more likely to involve the endocervical canal and vaginal wall. Clinical attention should be paid to the assessment of the canal by cervical canal sampling, which can include endocervical cytology, endocervical curettage (ECC) or type 3 excision, as well as a comprehensive examination of the vagina.

Grade of recommendation: ✓

An episode of postmenopausal bleeding warrants a complete gynaecological assessment. This includes HR-HPV testing, a cytology test for HR-HPV positive results, or cytology alone for primary cytology-based models if there is no result in the current screening round. Still, it is not an indication for colposcopy per se.

Grade of recommendation: ✓

Postmenopausal colposcopy can be difficult due to genitourinary syndrome of menopause (GSM/GUSM), which makes speculum insertion more painful and harder to tolerate. A course of intravaginal oestrogen cream or pessaries for 3–12 weeks before colposcopy may help. A vaginal retractor can be used in the case of vaginal prolapse. Cutting the tip from an ultrasound head cover/condom/glove finger to cover the speculum provides a 'make-shift' retractor. Once inserted and opened, this holds back the vaginal walls without discomfort. The smallest speculum possible for adequate exposure of the cervix and vaginal walls

is advised. Trauma to the cervical and vaginal epithelium can prevent colposcopy assessment if there are sub-epithelial petechiae or mucosal disruption.

Grade of recommendation: ✓

Diagnostic excisional procedure with a type 3 excision should be used to make a definitive diagnosis if the transformation zone (TZ) is not fully visible (i.e. TZ type 3). The location of any lesion (or upper limit of any lesion) cannot be identified colposcopically if the TZ is identified histologically within the excision specimen.

Grade of recommendation: ✓

Experience is necessary in pre-menopausal women until the colposcopist is confident in their technique and ability to perform a type 3 excision. When treating postmenopausal women, consulting with an expert colleague is advisable. It is also possible to use remote digital consultation to allow a colleague to supervise the procedure remotely. Specialist equipment needs to be medically suitable. Such a system may be worth the investment as it can enable a colposcopist to extend the level of care that they can provide.

Grade of recommendation: ✓

Summary of recommendations

- Type 3 TZ is more common in postmenopausal women, and colposcopy can easily damage atrophic epithelium.
- It is important to consider patient comfort during colposcopy; consider a course of topical oestrogen, lubricants, and vaginal retractors before colposcopy.
- An expert colposcopist should be able to offer a type 3 excision of the cervix.

Investigation and management of glandular abnormalities

Adenocarcinoma *in situ* (AIS) is recognised as the precursor to HPV-related invasive cervical adenocarcinoma. Diagnosis of atypical lesions less severe than AIS is controversial and not standardised. In some countries, as a synonym to AIS, glandular changes are termed cervical glandular intraepithelial neoplasia (CGIN). The incidence of AIS or CGIN is increasing, accounting for approximately 2 per 100,000 women [13]. It is unclear whether this is an absolute increase or due to improved ascertainment related to improvements in screening strategies.

The natural history is not as well understood as that of squamous disease. Still, AIS will likely progress to invasive cancer in many cases. Although glandular abnormalities on cytology are only 0.02 times the rate of squamous dyskaryosis, adenocarcinomas account for 20–25 % of all cervical cancer cases, and about 15 % are HPV-independent [14,15]. AIS and adenocarcinoma are associated with HPV infection, more often type 18 than type 16. HPV screening appears to diagnose more glandular lesions than cervical cytology alone [16]. A small subset of AIS is HPV-independent and histologically subdivided according to the WHO 2020 update on the Female Genital Tumors classification (5th edition) [17] with the most frequent gastric type cervical adenocarcinoma.

Diagnosis of AIS

Diagnosis is often made during the management of HSIL since these two entities can co-exist. Atypical changes in glandular cells are reported cytologically as atypical glandular cells (AGC), Not Otherwise Specified (AGC-NOS) endocervical, endometrial or glandular (not specified) or Favor Neoplastic (AGC-FN) endocervical or glandular (not specified), or AIS.

AGC is an uncommon cytologic diagnosis in the general population, from 0.0% (for conventional cytology preparation) to 1.0 (for ThinPrep) [18,19]. AGC is a poorly reproducible cytologic result [20]. 10 to 40 % of AGC are diagnosed as high-grade lesions and, more often, squamous origin. About 50 % of AGC HRHPV-positive results are associated with significant lesions (HSIL/CIN2, HSIL/CIN3, HSIL unspecified, AIS or

endocervical AGC). Less than 5 % of AGC HRHPV-negative are associated with significant precancerous or cancerous lesions [21,22].

All women with AGC and AIS must be referred for urgent colposcopy regardless of HPV status, except for cases with atypical endometrial cells. Endocervical sampling is recommended for all ages and all subcategories of AGC and AIS except pregnant women.

Grade of recommendation: ✓

- Women with samples reported as AGC in all subcategories except atypical endometrial cells on cytology should be immediately referred for colposcopic investigation with endocervical sampling for nonpregnant patients to exclude significant cervical lesions, including HSIL, regardless of HPV status. **Grade of recommendation:** ✓
- Women >35 years of age or <35 years of age but with endometrial cancer risk criteria (unexplained vaginal bleeding, obesity, or prolonged anovulation) need endometrial assessment by endometrial biopsy/endometrial sampling. **Grade of recommendation:** ✓
- Women with atypical endometrial cells specified (AGC-NOS or AGC-FN endometrial cells) should be referred to endometrial and endocervical sampling with optional colposcopy simultaneously. When no endometrial pathology is histologically confirmed, and colposcopy was not a part of the initial investigation, then colposcopy is recommended. **Grade of recommendation:** ✓
- Patients with non-cervical glandular lesions on cytology should be referred for gynaecological evaluation for urgent further investigation. **Grade of recommendation:** ✓

Colposcopic assessment of suspected AIS

Colposcopic recognition of AIS lesions is challenging. Most lesions are proximal to the new squamocolumnar junction (SCJ) or in the endocervical canal. Colposcopic signs of AIS are non-specific and can be confused with immature metaplasia. Appearances can mimic cervical ectopy. Colposcopic indicators suspicious of invasion findings are:

- Atypical vessels like roots, hairs, or Chinese characters (may be mimicked by cervicitis)
- Fragile vessels, necrosis, ulceration of cervical epithelium
- Coalescence of glandular papillae and nodularity is suspicious of AIS or invasion.

Grade of recommendation: ✓

The final diagnosis is made on histology with an adequate biopsy sampling of the epithelium.

- Colposcopic punch biopsy has a low sensitivity for AIS diagnosis and is inadequate to investigate glandular changes. **Grade of recommendation:** ✓
- A type 3 cylindrical excision, including the endocervical canal, is essential as 50 % of lesions are not detectable on colposcopy. **Grade of recommendation:** ✓
- Endocervical curettage (ECC) is preferred for assessing atypical glandular cytology and, if used, should be performed above the excision base following type 3 excision. **Grade of recommendation:** ✓

Treatment of AIS

AIS/CGIN requires a cylindrical-shaped type 3 excision to ensure the removal of endocervical crypts. With initial cytology AGC-NOS endocervical or glandular (not specified) (borderline glandular changes), colposcopy with biopsy and endocervical sampling may be sufficient to investigate. Still, with initial cytology AGC-FN or AIS, where there is suspicion of AIS, excisional treatment is mandatory as:

- Most glandular disease has an endocervical component. **Grade of recommendation:** ✓
- It is often not possible to determine the extent of endocervical involvement by colposcopy. **Grade of recommendation:** ✓
- Multicentric disease (skip lesions) occurs with glandular disease in 10–15 % of cases [23]. **Grade of recommendation:** D
- Ablative techniques are contraindicated for AIS as the depth of destruction needs an adequate depth of treatment, and invasive disease may be missed. **Grade of recommendation:** ✓
- Conservative management following type 3 excision is recommended only for those wishing to retain fertility if the excision margins of the specimen are free of disease, and invasion is excluded. **Grade of recommendation:** ✓

Conservative excisional techniques for AIS

- The treatment modality needs to provide an adequate sample (intact specimen with interpretable margins) for the histopathologist to allow assessment of the excision margins. **Grade of recommendation:** ✓
- The treatment modality needs to avoid or minimize thermal artefact. **Grade of recommendation:** ✓
- ECC is preferred in some countries following an excisional procedure in suspected glandular abnormalities to detect skip lesions. **Grade of recommendation:** ✓
- The extent of the cervical excision should be individualized.
 - In women who wish to preserve their fertility and who have a visible SCJ at colposcopy, a cylindrically shaped cervical excisional procedure, including the whole TZ and specimen length of at least 10 mm is preferred. **Grade of recommendation:** ✓
 - In women not desiring fertility, or where the SCJ is not visible at colposcopy, a cylindrical biopsy should be taken that includes all of the visible TZ and 18–20 mm of the endocervical canal. **Grade of recommendation:** ✓

If AIS involves the margins of an initial, conservative excision, a further attempt at conservative excision to exclude invasion and obtain negative margins should be preferred.

Grade of recommendation: ✓

Simple hysterectomy is the preferred treatment after a diagnostic excision procedure, which rules out invasive cancer and confirms negative margins, except for women with future pregnancy plans. Simple hysterectomy is preferred, too, after conservative management after childbearing.

Grade of recommendation: ✓

Follow-up after treatment of AIS

Clear resection margins do not give the same degree of reassurance against recurrence as with HSIL, as skip lesions may arise higher in the endocervical canal. The risk of recurrence is reported as three times higher. For women having a type 3 excision, long-term follow-up is essential.

Grade of recommendation: ✓

When the specimen margins are free of (including if treated by hysterectomy):

Follow-up at six months is recommended with HPV testing only, or a combination of cervical brush cytology and HPV testing as a test of cure (TOC) should be offered. If negative for HRHPV, a second TOC sample is taken 12 months later (i.e., 18 months after treatment). If this is also negative, the woman can be discharged to recall in three years as a minimum. ECC may also be acceptable. These are a minimum standard and extended follow-up and colposcopy can be offered.

Grade of recommendation: ✓

If cytology or HRHPV test is positive post-treatment, the woman must be referred to colposcopy. A high-risk HPV-DNA (HRHPV-DNA)

test is the most significant independent predictor of recurrent AIS or progression to invasive adenocarcinoma [16]. Women who have incompletely excised AIS and have declined re-excision should be followed up in the colposcopy clinic.

Grade of recommendation: B

Summary of recommendations

- Colposcopy +/- endocervical sampling is the initial management for all AGC cytology subcategories and AIS for nonpregnant women, except atypical endometrial cells.
- A diagnostic excisional procedure (type 3 excision) is recommended to identify disease and exclude invasion after colposcopy for all initial cytology results AGC-FN or AIS and no AIS or cancer in colposcopic histology. This also applies to AIS diagnosed in specimens after colposcopy.
- The definitive diagnostic procedure is excision of the TZ and a proportion of endocervical canal epithelium - at least 10 mm for patients who plan pregnancy (conservative management), to 18–20 mm when fertility is not desired.
- Long-term follow-up is essential for women with a type 3 excision, with referral to colposcopy if the patient has positive HRHPV or cytology.

Women with persistent HRHPV positivity with normal (NILM) or low-grade cytology (ASC-US or LSIL)

Cervical screening for HRHPV achieves greater sensitivity than cytology alone in detecting HSIL and a more significant reduction in cervical cancer incidence following the first screening round. However, the optimal clinical management of HRHPV-positive but low-grade cytology or cytology-negative is undecided. Generally, women with HRHPV persistence will either become HPV negative or develop HSIL/Cervical Intraepithelial Neoplasia (CIN) 2+ within six years, even with intensive clinical follow-up [24]. In this group, the overall prevalence of HSIL is low.

Treatment options for women with persistent HRHPV infection and normal or low-grade cytology

Ablative or excisional treatment modalities are ineffective for women with persistent HRHPV and normal or low-grade cytology without HSIL. After laser ablation, clearance of HRHPV at six months post-treatment has been only 60 % [25]. The success rates for medical management of HPV-related low-grade lesions (LSIL/CIN1) have been poor, either due to adverse events (Imiquimod, Interferon) or an unsatisfactory response (green tea, metronidazole-containing gel, 5-fluorouracil vaginal cream [25,26]. Alternative local treatment products are under evaluation and might offer a possibility in the future, but there is currently insufficient published evidence to allow recommendations.

Grade of recommendation: C

Ablative or excisional treatment modalities used for CIN have some effect in clearing HPV, but this must be weighed against their inherent risks, particularly for young women. Current management is conservative with repeat HRHPV testing. Clearance of HPV is associated with age and viral factors [27]. Older age is associated with reduced HPV clearance. In the short term, HPV clearance is higher with co-infections, but the effect is attenuated or reversed as infection persists.

Grade of recommendation: D

Summary of recommendations

- Women with hr-HPV persistence will either become HPV negative or may develop HSIL/CIN2+ within six years, even with intensive clinical follow-up. However, the overall prevalence of HSIL is low.

- Ablative or excisional treatment modalities are ineffective for women with persistent HRHPV and normal or low-grade cytology with negative or LSIL/CIN1 results.
- Current management is conservative repeat HRHPV testing in women with a fully visible TZ.

Colposcopy management of women with type 3 transformation zone

Managing women with a type 3 TZ is challenging for colposcopists and a concern for patients. Hysterectomy has become uncommon for benign gynaecological conditions, with conservative treatment options preferred. Additionally, with an increased upper age limit for screening in some countries, managing women with a type 3 TZ is an increasing problem in colposcopy practice. The inability to identify, assess and biopsy the extent of any lesion(s) can lead to higher rates of excisional treatments in women with low-grade cytology results to avoid missing a 'hidden' high-grade lesion or cervical cancer within the endocervical canal.

In countries where cervical screening is based on cervical cytology

Management of a woman with a type 3 TZ depends on the referral cytology and the results of any biopsies taken at colposcopy. Vaginal assessment is essential to exclude the presence of HSIL/Vaginal intraepithelial neoplasia (VaIN) 2+. **Grade of recommendation: ✓**

- For high-grade squamous referral cytology (atypical squamous cells, cannot rule out HSIL (ASC-H), HSIL, invasion), ECC or a diagnostic type 3 excision can assess the endocervical canal for unrecognised disease [28,29]. **Grade of recommendation: C**
- Low-grade squamous referral cytology (Atypical squamous cells of undetermined significance (ASC-US) or Low-grade squamous intraepithelial lesion (LSIL)) with the results of any biopsies being normal, repeat cytology or cytology and HPV testing at one year is acceptable. **Grade of recommendation: ✓ (see Fig. 1)**

For the patient with a TZ type 3, management depends on the referral HPV status, cervical cytology, and histology if available.

- For hr-HPV positive and high-grade cytology (ASC-H, HSIL, invasion), a diagnostic excisional procedure is acceptable. Alternatively, some countries will use ECC. **Grade of recommendation: ✓**
- HRHPV positive and cytology negative or low-grade (ASC-US, LSIL) may be managed by repeat HPV testing in 12 months. ECC may be used. **Grade of recommendation: ✓**
 - If then negative for HRHPV, the HRHPV test should be repeated at 24 months, and if again negative, the woman should be returned to routine screening. **Grade of recommendation: ✓**

Diagnostic excision of the TZ may be optionally considered if hr-HPV test positive with normal or low-grade cytology and colposcopy reported as Type 3 TZ if:

- have completed childbearing
- are anxious about cancer risk
- aged over 50 years
- may not be compliant with recommended surveillance
- aware of the risk of persistent HRHPV and risks of excision

Grade of recommendation: ✓

Role of endocervical curettage

Despite limited evidence, endocervical curettage (ECC) may be considered for all non-pregnant women referred for colposcopy with

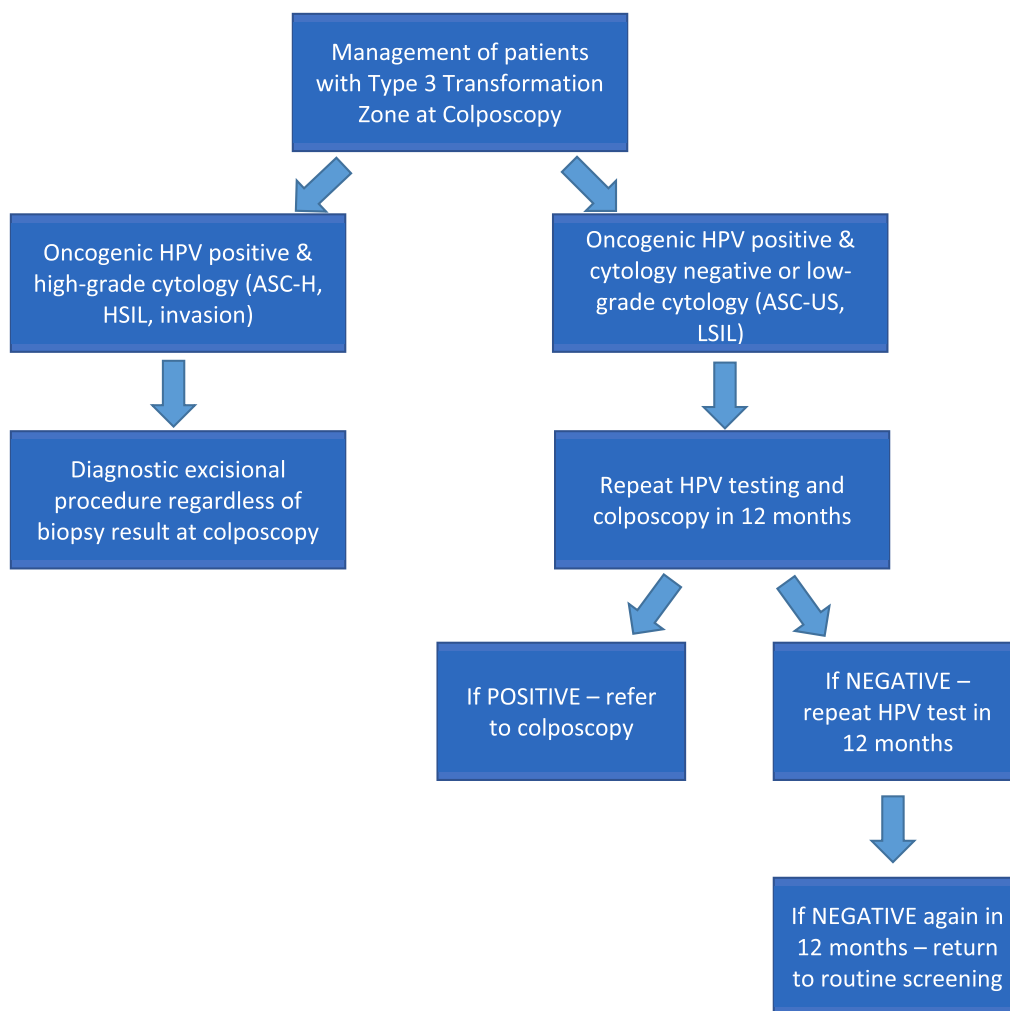


Fig. 1. A suggested pathway for countries where cervical screening is based on HPV testing with reflex cytology.

type 3 TZ. A positive ECC would support type 3 excision, whilst a negative ECC would support conservative management.

Grade of recommendation: ✓

Role of excision of TZ

Decisions about conducting an excision and the type of excision depend on other case characteristics:

- The reliability of the referral smear or other screening test
- The woman’s age and fertility plans
- The risk of default from follow-up
- The suspected grade of abnormality
- The availability of ancillary investigations (e.g., endocervical brush cytology, HPV testing, other biomarker tests).

Grade of recommendation: ✓

A formal review of the referral cytology, hr-HPV tests, colposcopy, and histology, if discrepancies exist before clinical decision-making about treatment or conservative management, for example, at a multi-disciplinary (MDT) meeting, may be helpful, especially for quality assessment and quality control.

Grade of recommendation: ✓

Summary of recommendations

- Managing women with a type 3 TZ is challenging for colposcopists and a concern for patients.
- Management of women with a type 3 TZ depends on the referral HRHPV status, cytology, and the results of any biopsies at colposcopy.
- Ancillary tests (immunocytochemical staining, molecular markers, HRHPV genotyping, ECC) and MDT review may aid decision-making.

Management of women with high-grade cytology and normal colposcopy

High-grade cytology, irrespective of HPV status, refers to HSIL and ASC-H. Normal colposcopy means that the colposcopic examination is adequate with a normal and visible TZ (TZ type is 1 or 2, so it can be fully assessed) and needs to include colposcopic examination of the vagina. The management of women with a type 3 is discussed above.

Grade of recommendation: ✓

Options for management include

1. Multiple punch biopsies +/- ECC except in pregnant women. **Grade of recommendation:** ✓
2. If colposcopy of the vagina is normal and histology is normal or LSIL, consider:

- a. Review of all results by MDT **Grade of recommendation: ✓**
- b. Diagnostic excisional procedure unless pregnant **Grade of recommendation: ✓**
- c. Conservative management with close monitoring with colposcopy and HRHPV test at six months. If there is any subsequent high-grade cytology or positive HRHPV test or HSIL/CIN2+ in histology, then excision of the TZ is recommended for full histopathological assessment. However, if HRHPV and histology are negative for one year, the women should be monitored with hr-HPV testing after the next 12 months. If the test is negative, women can return to routine screening in no more than three years. Any other abnormal test results must prompt referral to colposcopy [30]. **Grade of recommendation: D**
- d. Close surveillance, including cytology and HRHPV co-testing, with a one-year interval for two years. TZ excision should be performed if high-grade cytology is repeated on either visit. If HRHPV positive or any other abnormal cytology (except HSIL/ASC-H) is present, colposcopy should be performed. If cytology and HRHPV tests are negative on both visits, then screening is in 3 years [31]. **Grade of recommendation: A**
3. TZ excision may be acceptable at the first colposcopy visit ('See and Treat') only for HSIL cytology, except in younger women (<25 years), pregnant women and where future fertility is a consideration. However, repeating the colposcopy assessment, including the vagina, may subsequently identify disease. **Grade of recommendation: ✓**
4. Ablative treatments are not appropriate. **Grade of recommendation: ✓**
5. Hysterectomy can be considered if high-grade cytology persists and excision is not possible (due difficulty in accessing the cervix safely), if the patient has other gynaecological conditions which can be managed by surgery or if, after complete discussion, the patient prefers hysterectomy. However, there is a risk of unrecognised invasion in the residual cervical tissue. **Grade of recommendation: ✓**

Summary of recommendations

- Women with high-grade cytology and normal colposcopy (negative histology) should have close surveillance.
- Ablative treatments are not appropriate.
- Hysterectomy can be considered as a last resort where a woman has persistent high-grade cytology and excision is not possible.

Follow-up after treatment with CIN extending to the TZ specimen margins

Women treated for high-grade CIN are at increased risk for recurrent CIN and cervical cancer for up to 25 years. Factors for identifying women at higher risk include lesion size and grade, older age, treatment modality, incomplete lesion excision and persistent infection with HRHPV. Involvement of the endocervical margin represents a greater risk of residual CIN than involvement of the ectocervical margin. The involvement of 2 or 3 margins (ectocervical, endocervical and deep or lateral) increases the risk of CIN. HRHPV post-treatment predicts treatment failure more accurately (sensitivity 91 % and specificity 84 %) than margin status (sensitivity 56 % and specificity 84 %) [32]. Women over 50 with extensive lesions and/or affected margins or immunosuppression are a recognized high-risk group. The cumulative risk of no recurrent CIN in women >50 years with positive margins at five years is 57 % [33].

Follow-up after treatment

After incomplete excision, the relative risk of CIN2/3 is six times higher compared with complete excision [34]. Colposcopy is not helpful as a primary modality in the follow-up of patients after treatment for CIN

with involved surgical margins. HRHPV testing alone at six months is an accurate test of cure, and colposcopy should be reserved for patients who are HRHPV positive. In the case of cytology-based screening, cytology at 6, 12 and 24 months is advised. Any case of positive cytology requires referral to colposcopy.

Grade of recommendation: A

Routine repeat excision when margins are involved should be avoided, and these patients are primarily managed with active surveillance except in postmenopausal women. Repeat excision or hysterectomy may be considered according to the patient's fertility plans, follow-up HRHPV status with or without cytology, and the extent of the involved margin, especially margins, if the deep margin is involved. This should be discussed at the colposcopy multidisciplinary team meeting and with the patient.

Grade of recommendation: ✓ (see Fig. 2)

Grade of recommendation: ✓

Summary of recommendations

- Any excision or hysterectomy for a woman with a persistent positive HRHPV test will require cytological/colposcopic abnormality or CIN on biopsy to avoid overtreatment.
- Re-excision should be discussed with the post-menopausal patient with CIN2+ involving deep margins of excision specimen due to the increased risk of residual disease.

Follow-up after treatment of CIN with persistent HRHPV positivity

HRHPV persistence is the leading risk factor for recurrence after treatment [35]. The sensitivity of cytology, HPV-DNA and HPV-mRNA in detecting disease is high (almost 100 %), while the specificity for the three tests is 64.2, 52.4 and 78.9 %, respectively [36]. Women who test positive for HRHPV post-treatment are recommended to be seen for colposcopy though many will not have residual CIN detected.

Grade of recommendation: C

There is some evidence to support same-genotype persistence to improve risk discrimination for high-grade CIN compared with qualitative HPV testing without genotype-specific information [37]. Evaluating the HPV genotype persistence may represent a valid option to monitor these patients because relapses may only be detected in the persistence of the same genotype.

Grade of recommendation: D

Post-treatment HPV persistence is stratified by the time between treatment and the first HPV test

There is currently no consensus on when to test for HRHPV. There is substantial heterogeneity in post-treatment HPV testing practices and persistence estimates. Delaying the first post-treatment follow-up allows more women to clear HPV but delays residual disease detection. HPV and cytology co-testing allow women, irrespective of margin status, to safely continue with the general screening programme after a short post-treatment follow-up period. Providing a standard in follow-up after treatment should reduce "opportunistic" screening and allow return to routine screening.

Grade of recommendation: ✓

Summary of recommendations

- HRHPV testing after treatment of CIN 2+ is recommended for early detection of disease recurrence or progression.
- Women who test positive for HRHPV should return to colposcopy for assessment, irrespective of triage cytology.

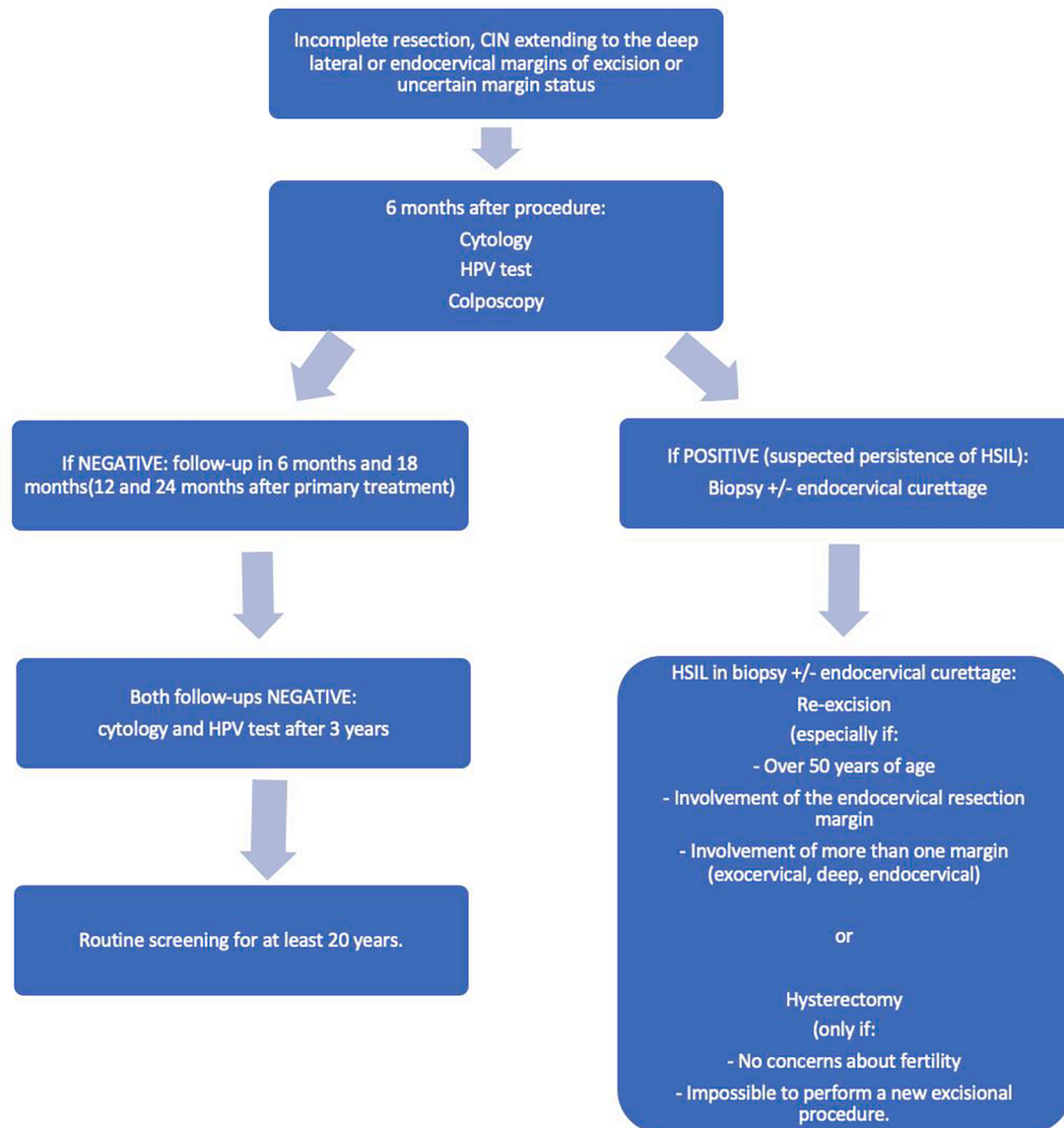


Fig. 2. Flowchart of suggested management of women with incomplete resection, margin involvement or uncertain margin status.

Surveillance of the lower genital tract for women with chronic immunosuppression

Management of women living with HIV

Women with human immunodeficiency virus (HIV)/acquired immune deficiency syndrome (AIDS) have significantly higher rates of cervical cancer than women in the general population worldwide, and there is a direct relationship between low CD4 T lymphocyte (CD4) cell count and cervical cancer risk.

Grade of recommendation: ✓

Screening

Women with HIV should participate in existing screening programmes, including primary HPV testing or cervical cytology-based screening, as available. Screening should begin by age 25–30 years, depending on the national programme and continue annually throughout a patient's lifetime.

Grade of recommendation: ✓

Abnormal results from cervical screening

Colposcopy referral is recommended for all cytology results of ASC-US or higher and all HPV-positive results. Women living with HIV have lower rates of regression of LSIL and increased rates of recurrence after treatment of CIN [38]. HIV-positive women are three times more likely to have cervical lesions than those without HIV. Any cervical lesion detected during colposcopy should be biopsied to inform management.

Grade of recommendation: C

Treatment of CIN in women living with HIV

Low-grade lesions should not be treated as these are likely to represent persistent HRHPV infection. Cytology and colposcopy examination are recommended every 6–12 months to monitor for progression. If regression is not detected within 24 months, treatment by excision or ablation should be considered as the risk of progression and the time of progression to HSIL is higher in HIV-infected women. High-grade CIN should be treated by excisional methods within six months to reduce the risk of loss to follow-up. However, in pregnant women, good practice includes waiting until after pregnancy.

Grade of recommendation: ✓

Management of women with non-HIV chronic immunosuppression

Individuals taking maintenance immunosuppression medication after transplantation or managing autoimmune disorders, including high-dose steroids, tacrolimus, and biologics, who have no history of CIN should have cervical screening per the national guidelines for the general population. Any abnormal screening result should be managed as for women with HIV.

Grade of recommendation: ✓

Summary of recommendations

- Women with HIV/AIDS are at a significantly higher risk of developing cervical cancer and require annual screening.
- Any cervical lesion detected during colposcopy in a woman with HIV should be biopsied.
- Women who are chronically immunosuppressed, unrelated to HIV, should be monitored as per the national guidelines for the general population. Still, any abnormal result should be managed per the guidance for women with HIV.

The role of adjuncts to colposcopy

In recent years, new adjunctive technology has become more widely available in colposcopy, but uptake is not universal.

The Dynamic Spectral Imaging System (DYSIS) colposcope with DYSISmap measures the aceto-whitening reaction on the cervix and summarizes it as an intuitive map. ZedScan uses electrical impedance spectroscopy (EIS) to detect abnormal tissue on the cervix according to

Appendix 1

1. Explanation of guidelines and evidence levels

Clinical guidelines are: ‘systematically developed statements which assist clinicians and patients in making decisions about appropriate treatment for specific conditions.’ Each guideline is systematically developed using a standardised methodology. Exact details of this process can be found in Clinical Governance Advice No. 1 *Development of RCOG Green-top Guidelines* (available on the RCOG website at <http://www.rcog.org.uk/green-top-development>).

These recommendations are not intended to dictate an exclusive course of management or treatment. They must be evaluated with reference to individual patient needs, resources, and limitations unique to the institution and variations in local populations. It is hoped that this process of local ownership will help to incorporate these guidelines into routine practice. Attention is drawn to areas of clinical uncertainty where further research may be indicated.

The evidence used in this guideline was graded using the scheme below and the recommendations formulated in a similar fashion with a standardised grading scheme.

Classification of evidence levels

| | |
|-----|---|
| 1++ | High-quality <i>meta</i> -analyses, systematic reviews of randomised controlled trials or randomised controlled trials with a very low risk of bias |
| 1+ | Well-conducted <i>meta</i> -analyses, systematic reviews of randomised controlled trials or randomised controlled trials with a low risk of bias |
| 1– | Meta-analyses, systematic reviews of randomised controlled trials or randomised controlled trials with a high risk of bias |
| 2++ | High-quality systematic reviews of case–control or cohort studies or high-quality case–control or cohort studies with a very low risk of confounding, bias or chance and a high probability that the relationship is causal |
| 2+ | Well-conducted case–control or cohort studies with a low risk of confounding, bias or chance and a moderate probability that the relationship is causal |
| 2– | Case–control or cohort studies with a high risk of confounding, bias or chance and a significant risk that the relationship is not causal |
| 3 | Non-analytical studies, e.g. case reports, case series |
| 4 | Expert opinion |

Grades of Recommendation

the tissue’s electrical properties.

DYSIS technology may increase the sensitivity of detecting CIN2+ lesions significantly compared to colposcopy alone [39,40] but this is due to reduced specificity. This increase has been shown, but the degree of expansion varies across studies from 7 % to 30 % [41,42].

Grade of recommendation: C

Fewer data are available for ZedScan, but similar results have been reported with increased sensitivity for CIN2+ lesions and a reduction in specificity [43], particularly in non-HPV16 patients [44]. There is insufficient published evidence to comment on other digital colposcopy techniques, like TruScreen, Polarprobe and LuViva.

Grade of recommendation: C

HPV testing-based screening programs, together with HPV vaccination programs, will decrease the number of high-grade screening referrals to colposcopy, and adjunctive technology can support the colposcopist in decision-making in the future [45,46].

Grade of recommendation: A

Summary of recommendations

- Adjunctive technology may be used as a diagnostic aid in colposcopy.
- Treatment decisions should not be based only on adjunctive technology.
- Further studies are called for to determine the effect of these technologies, particularly for those with less evidence for use.

Declaration of Competing Interest

The authors declare that they have no known competing financial interests or personal relationships that could have appeared to influence the work reported in this paper.

| | |
|----------------------------|---|
| Grade of Recommendation: A | At least one <i>meta</i> -analysis, systematic reviews or RCT rated as 1++, and directly applicable to the target population; or a systematic review of RCTs or a body of evidence consisting principally of studies rated as 1+, directly applicable to the target population and demonstrating overall consistency of results |
| Grade of Recommendation: B | A body of evidence including studies rated as 2++ directly applicable to the target population, and demonstrating overall consistency of results; or Extrapolated evidence from studies rated as 1++ or 1+ |
| Grade of Recommendation: C | A body of evidence including studies rated as 2+ directly applicable to the target population, and demonstrating overall consistency of results; or Extrapolated evidence from studies rated as 2++ |
| Grade of Recommendation: D | Evidence level 3 or 4; or Extrapolated evidence from studies rated as 2+ |

Good Practice Points

| | |
|----------------------------|---|
| Grade of Recommendation: ✓ | Recommended best practice based on the clinical experience of the guideline development group |
|----------------------------|---|

References:

- Redman CWE, Kesic V, Cruickshank ME, Gultekin M, Carcopino X, Castro M, et al. European consensus statement on essential colposcopy. *Eur J Obstet Gynecol Reprod Biol* 2021;256:57–62.
- Jach R, Mazurec M, Trzeszcz M, Bartosinska-Dyc A, Galarowicz B, Kedzia W, et al. Colposcopy 2020 – Colposcopy Protocols: A Summary of the Clinical Experts Consensus Guidelines of the Polish Society of Colposcopy and Cervical Pathophysiology and the Polish Society of Gynaecologists and Obstetricians. *Ginekol Pol* 2020;91(6):362–71.
- Jach R, Mazurec M, Trzeszcz M, Stukan M, Kolawa W, Markowska A, Knapp P, Galarowicz B, Fuchs A, Florczak K. Cervical Cancer screening guidelines of the Polish Society of Gynecologists and Obstetricians - June 2022. The Polish Society for Colposcopy and Cervical Pathology Statement - A Summary. August 2022. (in press).
- Preti M, Joura E, Vieira-Baptista P, Van Beurden M, Bevilacqua F, Bleeker MCG, et al. The European Society of Gynaecological Oncology (ESGO), the International Society for the Study of Vulvovaginal Disease (ISSVD), the European College for the Study of Vulval Disease (ECSVD) and the European Federation for Colposcopy (EFC) Consensus Statements on Pre-invasive Vulvar Lesions. *J Low Genit Tract Dis* 2022;26(3):229–44.
- Grimm D, Lang I, Prieske K, Jaeger A, Muller V, Kuerti S, et al. Course of cervical intraepithelial neoplasia diagnosed during pregnancy. *Arch Gynecol Obstet* 2020; 301(6):1503–12.
- Bracic T, Reich O, Taumberger N, Tamussino K, Trutnovsky G. Does mode of delivery impact the course of cervical dysplasia in pregnancy? *Eur J Obstet Gynecol Reprod Biol* 2020;274:13–8.
- Mitsuhashi A, Sekiya S. Loop electrosurgical excision procedure (LEEP) during first trimester of pregnancy. *Int J Gynaecol Obstet* 2000;71(3):237–9.
- Fambrini M, Penna C, Fallani MG, Pieralli A, Mattei A, Scarselli G, et al. Feasibility and outcome of laser CO2 conization performed within the 18th week of gestation. *Int J Gynecol Cancer* 2007;17(1):127–31.
- Siegler E, Lavie O, Amit A, Vaknin Z, Auslander R, Blumenfeld Z, et al. Should the Risk of Invasive Cancer in Pregnancy and the Safety of Loop Electrosurgical Excision Procedure during the First 15 Weeks change our practice? *J Low Genit Tract Dis* 2017;21(4):299–303.
- Sawaya GF, Grady D, Kerlikowske K, et al. The positive predictive value of cervical smears in previously screened postmenopausal women: the Heart and Estrogen/progestin Replacement Study (HERS). *Ann Intern Med* 2000;133(12):942–50.
- McHugh KE, Reynolds JP, Suarez AA. Postmenopausal Squamous Atypia: Cytologic Features, Hybrid Capture 2 Tests and Contribution to the ASCUS Pool. *Acta Cytol* 2018;62(5–6):418–22.
- van der Horst J, Siebers AG, Bulten J, Massuger LF, de Kok IM. Increasing incidence of invasive and in situ cervical adenocarcinoma in the Netherlands during 2004–2013. *Cancer Med* 2017;6(2):416–23. <https://doi.org/10.1002/cam4.971>.
- Katki HA, Kinney WK, Fetterman B, Lorey T, Poitras NE, Cheung L, et al. Cervical cancer risk for women undergoing concurrent testing for human papillomavirus and cervical cytology: a population-based study in routine clinical practice. *Lancet Oncol* 2011 Jul;12(7):663–72.
- Pirog EC. Cervical Adenocarcinoma: Diagnosis of Human Papillomavirus-Positive and Human Papillomavirus-Negative Tumors. *Arch Pathol Lab Med* 2017;141: 1653–67.
- Jenkins D, Molijn A, Kazem S, Pirog EC, Alemany L, de Sanjosé S, et al. Molecular and pathological basis of HPV-negative cervical adenocarcinoma seen in a global study. *Int J Cancer* 2020;147:2526–36.
- Costa S, Venturoli S, Origoni M, Preti M, Mariani L, Cristoforoni P, et al. Performance of HPV DNA testing in the follow-up after treatment of high-grade cervical lesions, adenocarcinoma in situ (AIS) and microinvasive carcinoma. *Eancer* 2015;9:528.
- Höhn AK, Brambs CE, Hiller GGR, May D, Schmoekel E, Horn L-C. 2020 WHO Classification of Female Genital Tumors. *Geburtshilfe Frauenheilkd* 2021;81(10): 1145–53. <https://doi.org/10.1055/a-1545-4279>. Epub 2021 Oct 6. PMID: 34629493; PMCID: PMC8494521.
- Davey DD, Souers RJ, Goodrich K, Mody DR, Tabbara SO, Booth CN. Bethesda 2014 Implementation and Human Papillomavirus Primary Screening: Practices of Laboratories Participating in the College of American Pathologists PAP Education Program. *Arch Pathol Lab Med* 2019 Oct;143(10):1196–202.
- Trzeszcz M, Mazurec M, Jach R, Mazurec K, Jach Z, Kotkowska-Szeps I, et al. Liquid-based screening tests results: HPV, liquid-based cytology, and P16/Ki67 dual-staining in private-based opportunistic cervical cancer screening. *Diagnostics (Basel)* 2021 Aug 5;11(8):1420.
- Lee KR, Darragh TM, Joste NE, Krane JF, Sherman ME, Hurley LB, et al. Atypical glandular cells of undetermined significance (AGUS): interobserver reproducibility in cervical smears and corresponding thin-layer preparations. *Am J Clin Pathol* 2002;117(1):96–102.
- Nayar R, Wilbur DC. The Bethesda system for reporting cervical cytology—definitions, criteria, and explanatory Notes. Springer International Publishing; 2015.
- Zhao C, Florea A, Austin RM. Clinical utility of adjunctive high-risk human papillomavirus DNA testing in women with Papanicolaou test findings of atypical glandular cells. *Arch Pathol Lab Med* 2010 Jan;134(1):103–8.
- Zaino RJ. Adenocarcinoma in situ, glandular dysplasia and early invasive adenocarcinoma of the uterine cervix. *Int J Gynecol Pathol* 2002;21:314–26.
- Elfgren K, Elfström KM, Naucner P, et al. Management of women with human papillomavirus persistence: long-term follow-up of a randomized clinical trial. *Am J Obstet Gynecol* 2017;216:264.
- Navarro Santana B, Sanz Baro R, Orozco R, Plaza Arranz J. Cervical vaporization in LSIL and persistent HPV infection. *Taiwan J Obstet Gynecol* 2018;57(4):475–8.
- Holmes MM, Weaver 2nd SH, Vermillion ST. A randomized, double-blind, placebo-controlled trial of 5-fluorouracil for the treatment of cervicovaginal human papillomavirus. *Infect Dis Obstet Gynecol* 1999;7:186–9.
- Li W, Meng Y, Wang Yi, Cheng X, Wang C, Xiao S, et al. Association of age and viral factors with high-risk HPV persistence: A retrospective follow-up study. *Gynecol Oncol* 2019;154(2):345–53.
- Van der Marel J, Rodriguez A, Del Pino M, et al. The value of endocervical curettage in addition to biopsies in patients referred to colposcopy. *J Low Genit Tract Dis* 2015;19:282–7.
- Liu AH, Walker J, Gage JC, et al. Diagnosis of cervical precancers by endocervical curettage at colposcopy of patients with abnormal cervical cytology. *Obstet Gynecol* 2017;130:1218–25.
- Perkins RB, Schiffman M, Guido RS. The next generation of cervical cancer screening programs: making the case for risk-based guidelines. *Curr Probl Cancer* 2018;42(5):521–6.
- Silver MI, Andrews J, Cooper CK, Gage JC, Gold MA, Khan MJ, et al. Risk of cervical intraepithelial neoplasia 2 or worse by cytology, human papillomavirus 16/18, and colposcopy impression: a systematic review and meta-analysis. *Obstet Gynecol* 2018;132(3):725–35.
- Arbyn M, Redman CWE, Verdoordt F, Kyrgiou M, Tzafetas M, Ghaem-Maghani S, et al. Incomplete excision of cervical precancer as a predictor of treatment failure: a systematic review and meta-analysis. *Lancet Oncol* 2017;18(12):1665–79.
- Flanely G, Bolger B, Fawzi H, De Barros LA, Monaghan JM. Could schedules be modified according to risk of recurrence? *Br J Obstet Gynaecol* 2001;108:1025–30.
- Ghaem-Maghani S, Sagi S, Majeed G, Soutter WP. Incomplete excision of cervical intraepithelial neoplasia and risk of treatment failure: a meta-analysis. *Lancet Oncol* 2007;8(11):985–93.
- Cuschieri K, Bhatia R, Cruickshank M, Hillemanns P, Arbyn M. HPV testing in the context of post-treatment follow up (test of cure). *J Clin Virol* 2016;76(Suppl 1): S56–61.
- Tisi G, Gargiulo F, Gozzini E, Baronchelli C, Odcino F, Salinaro F, et al. Role of HPV DNA, HPV mRNA and cytology in the follow-up of women treated for cervical dysplasia. *APMIS* 2019 Apr;127(4):196–201. <https://doi.org/10.1111/apm.12931>. Epub 2019 Feb 27 PMID: 30815926.
- Bruno MT, Cassaro N, Garofalo S, Boemi S. HPV16 persistent infection and recurrent disease after LEEP. *Virol J* 2019;16(1):148.
- Denslow SA, Rositch AF, Firnhaber C, Ting J, Smith JS. Incidence and progression of cervical lesions in women with HIV: a systematic global review. *Int J STD AIDS* 2014;25(3):163–77.
- Budithi S, Peevor R, Pugh D, Papagiannakis E, Durman A, Banu N, et al. Evaluating colposcopy with dynamic spectral imaging during routine practice at five colposcopy clinics in Wales: clinical performance. *Gynecol Obstet Invest* 2018;83(3):234–40.

- [40] Louwers JA, Zaal A, Kocken M, Berkhof J, Papagiannakis E, Snijders PJF, et al. The performance of Dynamic Spectral Imaging colposcopy depends on indication for referrals. *Gynecol Oncol* 2015;139(3):452–7.
- [41] Cholkari-Singh A, Lavin PT, Olson CG, Papagiannakis E, Weinberg L. Digital colposcopy with dynamic spectral imaging for detection of cervical Intraepithelial Neoplasia 2 in low-grade referrals: the IMPROVE-COLPO study. *J Low Genit Tract Dis* 2018;22(1):21–6.
- [42] Bargum Booth B, Petersen LK, Blaakaer J, Johansen T, Mertz H, Dahl K, et al. Accuracy of colposcopy-directed biopsy vs dynamic spectral imaging directed biopsy in correctly identifying the grade of cervical dysplasia in women undergoing conization: A methodological study. *Acta Obstet Gynecol Scand* 2020; 99(8):1064–70.
- [43] Tidy JA, Brown BH, Healey TJ, Daayana S, Martin M, Prendiville W, et al. Accuracy of detection of high-grade cervical intraepithelial neoplasia using electrical impedance spectroscopy with colposcopy. *BJOG* 2013;120(4):400–11.
- [44] Macdonald MC, Brown BH, Lyon RE, Healey TJ, Prendiville WJ, Duncan WB, et al. Detection of cervical intraepithelial neoplasia in vivo using electrical impedance spectroscopy and colposcopy. *Gynecol Oncol* 2008;108:218–24.
- [45] Peron M, Llewellyn A, Moe-Byrne T, Walker S, Walton M, Harden M, et al. Adjunctive colposcopy technologies for assessing suspected cervical abnormalities: systematic reviews and economic evaluation. *Health Technol Assess* 2018;22(54): 1–260.
- [46] Byrom J, Dunn P, Ferguson G, Leeson S, Redman C, Smith J, et al. Using technology to harmonise treatment approaches in colposcopy in the face of a changing environment. *Eur J Obstet Gynecol Reprod Biol* 2020;255:40–3.