



Case Report

Viral exanthem with “Spins and needles sensation” on extremities of a COVID-19 patient: A self-reported case from an Indonesian medical frontliner



Bayushi Eka Putra^{a,*}, Suko Adiar^a, Santi Rahayu Dewayanti^b, Dafisah Arifa Juzar^a

^a Department of Cardiology and Vascular Medicine, Faculty of Medicine Universitas Indonesia/Harapan Kita National Cardiovascular Centre, Jakarta, Indonesia

^b Harapan Kita National Cardiovascular Centre, Faculty of Medicine Universitas Indonesia, Jakarta, Indonesia

ARTICLE INFO

Article history:

Received 11 April 2020

Received in revised form 4 May 2020

Accepted 5 May 2020

Keywords:

COVID-19

Cutaneous manifestation

Pins and needles sensation

Medical personnel

ABSTRACT

Cutaneous manifestation is a newly reported clinical manifestation of COVID-19 infection. The clinical description of cutaneous manifestation is still not fully described. Our patient, a medical person, had viral exanthem distributed in the extremities along with a “Spins and needles sensation,” which differs from a previously published paper on cutaneous manifestations. The differential diagnosis of drug-induced skin rash and hand-foot-mouth disease was ruled out based on the patient’s previous history and course of the disease.

© 2020 The Author(s). Published by Elsevier Ltd on behalf of International Society for Infectious Diseases. This is an open access article under the CC BY-NC-ND license (<http://creativecommons.org/licenses/by-nc-nd/4.0/>).

Introduction

As of May 4, 2020, the number of coronavirus (COVID-19) patients keeps increasing worldwide, reaching a total of 3,515,177 confirmed cases. From that number, 1,133,932 patients recovered, and 245,607 patients died ([Coronavirus Update \(Live\), 2020](#)). In Indonesia, there were 11,192 confirmed cases with 1,876 already recovered, and 845 died ([Gugus Tugas Percepatan. Peta Sebaran, 2020](#)). Thus, the number keeps increasing as the spreading is rapid from person to person ([McIntosh, 2020](#)).

The widely known manifestations of COVID-19 patients are fever (99% of patients), fatigue (70% of patients), dry cough (59 percents of patients), anorexia (40% of patients, along with myalgias, dyspnea, and sputum production, each under the prevalence of 40%, as reported in the clinical characteristic of patients in Wuhan, China ([Wang et al., 2020](#)). These clinical manifestations are paramount for the initial screening of COVID-19 patients. Recently, it was mentioned that 20.4% of COVID-19 patients in Italy developed cutaneous signs of erythematous rash, widespread urticaria, and chickenpox-like vesicles, with the trunk as the centrally involved region ([Recalcati, 2020](#)).

Cardiovascular disease is among the most common comorbidity found in COVID-19 patients. This study will highlight a self-

reported case of exanthema, which manifested in the extremities of a medical person serving in the isolation room of a National Cardiovascular Center, who contracted COVID-19. The goal is to describe in detail the clinical manifestation of COVID-19 patients, especially the cutaneous manifestation that was just recently known to present in COVID-19 infection along with its appearance after treatment.

Case report

A 29-year-old Asian Male experienced a fever of 38.4–38.7 degrees Celsius in the first to the third days. The patient was a medical person in the National Cardiovascular Centre, Harapan Kita, Indonesia. The history of contact was with a patient who tested positive for COVID-19.

The fever tended to increase in the afternoon, peaked in the evening and lasted for the first three days. Back pain was present during every feverish period. Myalgia, sore throat, and dry cough were also prominent for the first three days of symptoms ([Figure 1](#)). Oral paracetamol 500 mg was only given if the body temperature was above 38 °C, to monitor the pattern of the fever. Azithromycin 1 × 500 mg was started at day two of the symptoms. The patient’s blood pressure was 120/80 mmHg, with a pulse rate of 80 bpm. No murmur or irregularity from heart auscultation was observed. No crackles or wheezing was heard from lung auscultation. Other aspects of the physical examination were normal.

* Corresponding author.

E-mail address: ekaputra_bayushi@yahoo.com (B.E. Putra).

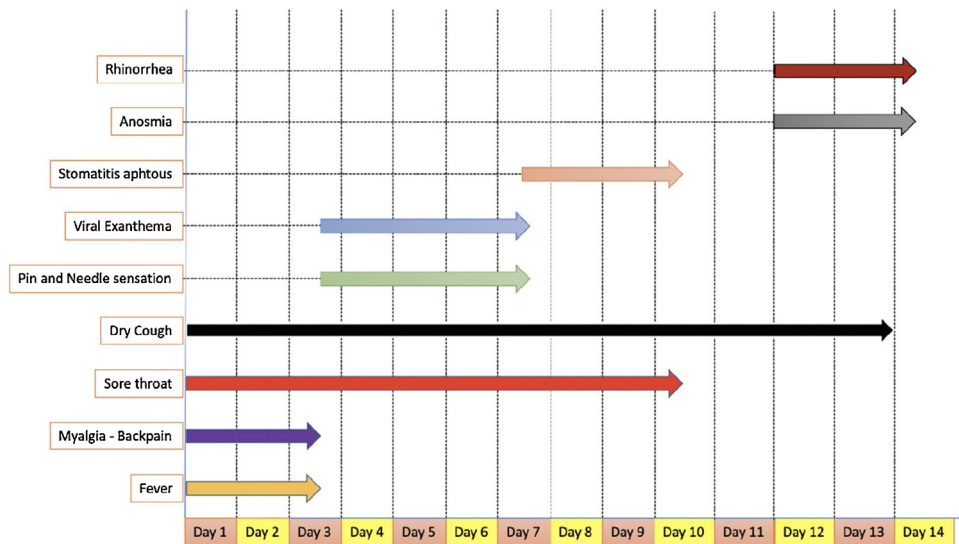


Figure 1. Onset and Duration of Symptoms of the Patient During the Follow-Up Period of 14 Days.

Laboratory examination on day two of symptoms showed: Hemoglobin 13.6 g/dL, Hematocrit 42.7%, Thrombocyte 232.000/ μ L, Leukocyte 8800/ μ L with basophil 0.2%, Eosinophil 0.1%, Neutrophil 88.7%, Lymphocyte 6.6% (Lymphocyte absolute 528/ μ L), and Monocyte 4.4%. The high sensitive c-reactive protein (CRP) was elevated to 46.1 mg/L (normal level \leq 10 mg/L). The neutrophil to lymphocyte ratio was 13.44; meanwhile, the lymphocyte to CRP ratio was 11.47. Chest X-ray on day three of symptoms and follow-up lung computed tomography on day seven of symptoms, showed a normal cardiac silhouette with no infiltrate nor cranialization of lung vascularization.

Oropharyngeal and nasopharyngeal swab samples were taken on day three of symptoms for polymerase chain reaction (PCR) examination for COVID-19 DNA strain. Treatment for COVID-19 was planned to wait for the PCR result.

Fever resolved on day three of symptoms; however, there was pins and needles sensation at the fingertips and the toe tips, along with the appearance of discrete multiple lenticular redness papules with a maximum diameter of 3 mm which appeared at the extremities (Figure 2; **Upper and Middle Row**). The lesion did not spread to the trunk and became more apparent on days four and five of symptoms. Considering the newly reported case of cutaneous manifestation of COVID-19, treatment for COVID-19 by local protocol treatment was administered on day four of symptoms without waiting for the PCR result: azithromycin 1 \times 500 mg was given for ten days, hydroxychloroquine 1 \times 400 mg was given for ten days, oseltamivir 2 \times 75 mg was given for ten days, vitamin C 3 \times 1000 mg was given for 14 days, and vitamin D 1 \times 5000 IU was given for 14 days.

On day six, the lesions lessened in number, and on day seven, the lesions darkened in color. The pins and needles sensation persisted to day seven (visual analog score 3–4) and disappeared on day eight of the symptoms. The toe tips' and fingertips' skin was thickened and exfoliated on day fourteen of symptoms (Figure 2; **Bottom Row**). Stomatitis aphthous was noticed on day seven and resolved on day ten after treatment with typical hygiene oral care. On days ten and eleven, no other symptoms were noted, aside from dry cough. However, on day twelve, rhinorrhea and anosmia were apparent and persisted until day fourteen.

The result of a nasopharyngeal and oropharyngeal swab using the PCR technique confirmed COVID-19 infection on the tenth day.

On day eight of treatment (Day nine of symptoms), a newly published treatment protocol from the Indonesian Pulmonologist Association stating the use of azithromycin 1 \times 500 mg should be given only for three days, hydroxychloroquine 1 \times 400 mg should be given only for five days, and oseltamivir 2 \times 75 mg should be given only for five days for a mild presentation of COVID-19 infection. Oseltamivir, hydroxychloroquine, and azithromycin were stopped on day eight of treatment following this treatment protocol.

Discussion

Cutaneous manifestation was a new finding in COVID-19 patients. It was first reported in Italy from 18 patients (20.4%) with cutaneous manifestation among a total of 88 patients with COVID-19 (Recalcati, 2020). In our case, the onset started after the fever has subsided, notably on days four and five of symptoms. Regarding the Italian paper mentioned above, the onset of cutaneous manifestation was variable among the subjects, either before or after hospitalization; however, the onset was not clearly documented. The trunk area was also mentioned as the principally affected region in the Italian paper (Recalcati, 2020); however, we found cutaneous lesions to be distributed only in the extremities, accompanied by a pins and needles sensation that had not been previously mentioned.

Skin eruptions were known to be a great imitator and might be caused by any kind of etiology, including drug eruptions. Systemic antibiotics and antiviral medications used in COVID-19 treatment such as chloroquine, cyclosporine, and azithromycin were thought to cause skin eruptions (Lee, 2020). However, this might not be the case in our patient. The patient was known to have not taken any new drugs during the previous 15 days aside from azithromycin, which was started two days before the skin lesion erupted. Azithromycin was known to cause fixed drug eruption and erythema multiforme. However, target lesions that were pathognomonic for erythema multiforme were not present, and despite continued use of azithromycin from day two to day eleven of symptoms, the skin lesions improved and resolved from day seven of symptoms, proving the skin eruptions to be caused by viral exanthema (Shah et al., 2014; An et al., 2017).

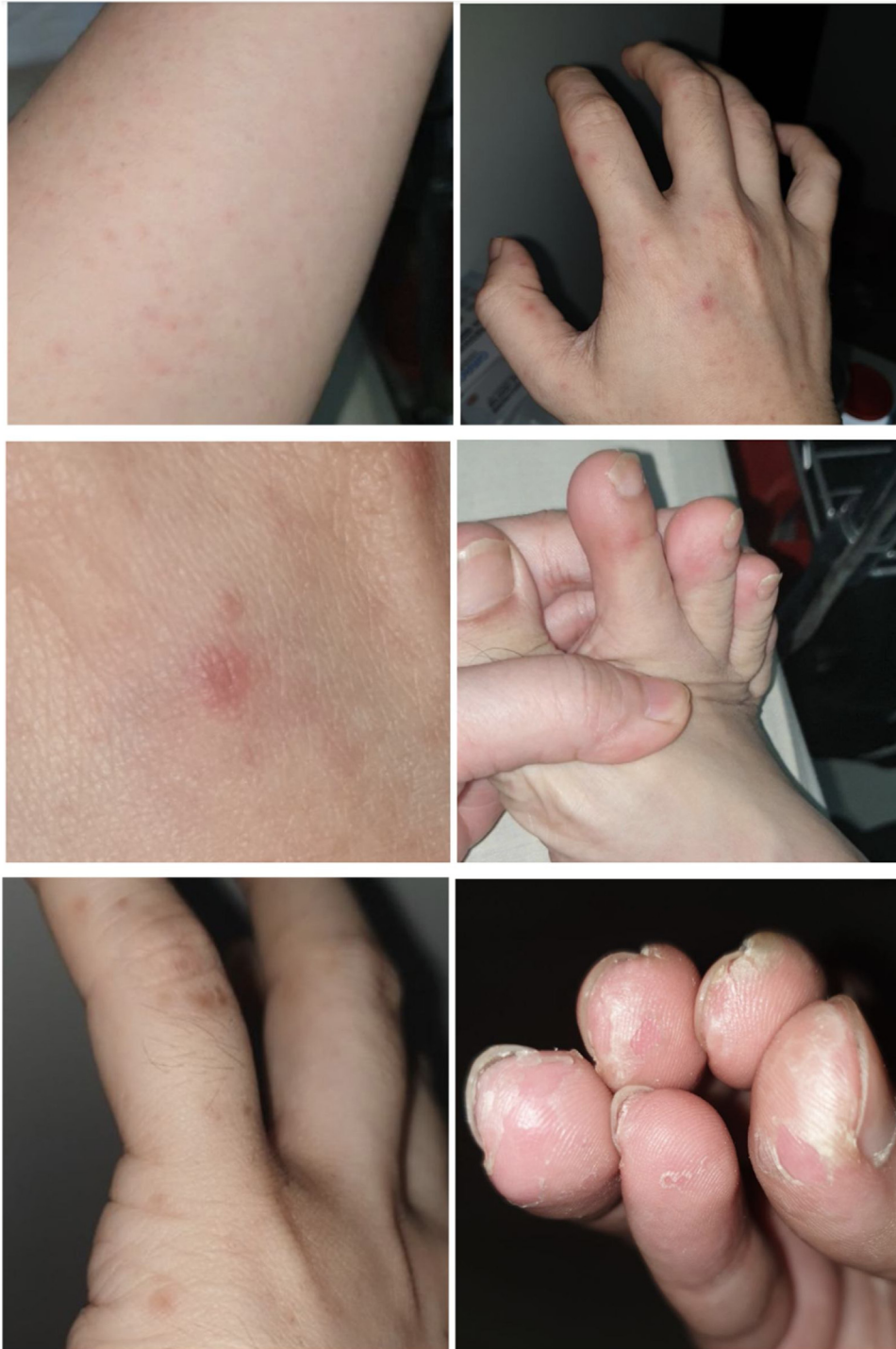

Figure 2. Viral Exanthem Manifestations. *Upper and middle row:* Distribution of Discrete Lenticular Lesions in Extremities on days three to five; *Bottom row* showing resolution of lesions on day seven with exfoliation of skin in fingertips on day fourteen.

Aside from due to drug eruption, viral exanthem distributed in the extremities area was at first thought to be the manifestation of hand, foot, and mouth disease (HFMD). The appearance of stomatitis aphthous also supported a diagnosis of HFMD (Knöpfel et al., 2019). However, there are several characteristics of HFMD which did not fit our patient: first, the most common age-group of HFMD was among

patients below five years of age; second, the mucosal lesions usually erupt in the first two days; third, lesions in buttocks and genitalia are usually present (Zhao et al., 2016; Hand-Foot-and-Mouth Disease (HFMD), 2020). Moreover, the PCR naso-oropharyngeal swab examination clearly stated the presence of COVID-19 infection in our patient, and no previous contact with an HFMD patient was noted.

Although exfoliation from the skin eruption might be normal, thickening of skin along with exfoliation at the fingertips should raise questions regarding the possibility of finding COVID-19 DNA in the exfoliating area and the probability of viral transmission through the skin break from the exfoliating area. Research on this area should be strongly encouraged.

Conflicts of interest

There are no conflicts of interest.

Funding source

Publication is supported by National Cardiovascular Centre Harapan Kita.

Ethical approval

The first author, who is also the patient in this case report, has given permission for the publication of this case report and the accompanying images.

References

An I, Demir V, Akdeniz S. Fixed drug eruption probably induced by azithromycin. *Australas J Dermatol* 2017;58(November (4)):e253–4.

- Coronavirus Update (Live). 1,521,030 cases and 88,565 deaths from COVID-19 virus pandemic – worldometer. [Cited 4 May 2020]. Available from: 2020. <https://www.worldometers.info/coronavirus/>.
- Gugus Tugas Percepatan. Peta Sebaran. Gugus Tugas Percepatan Penanganan COVID-19. [Cited 3 May 2020]. Available from: 2020. <https://covid19.go.id/peta-sebaran>.
- Hand-Foot-and-Mouth Disease (HFMD). Practice essentials, background, pathophysiology. [Cited 11 April 2020]. Available from: 2020. <https://emedicine.medscape.com/article/218402-overview>.
- Knöpfel N, Noguera-Morel L, Latour I, Torrelo A. Viral exanthems in children: a great imitator. *Clin Dermatol* 2019;37(May (3)):213–26.
- Lee C-H. Role of dermatologists in the uprising of the novel corona virus (COVID-19): perspectives and opportunities. *Dermatol Sin* 2020;38(January (1)):1.
- McIntosh Kenneth. Coronavirus disease 2019 (COVID-19): Epidemiology, virology, clinical features, diagnosis, and prevention. UpToDate; 2020 [Cited 9 April 2020]. Available from: https://www.uptodate.com/contents/coronavirus-disease-2019-covid-19?search=covid%2019&source=search_result&selectedTitle=1~120&usage_type=default&display_rank=1.
- Recalcati S. Cutaneous manifestations in COVID-19: a first perspective. *J Eur Acad Dermatol Venereol* 2020;(March). Available from: <https://doi.org/10.1111/jdv.16387>.
- Shah SN, Chauhan GR, Manjunatha BS, Dagrug K. Drug induced erythema multiforme: two case series with review of literature. *J Clin Diagn Res* 2014;8(September (9)):ZH01–4.
- Wang D, Hu B, Hu C, Zhu F, Liu X, Zhang J, et al. Clinical characteristics of 138 hospitalized patients with 2019 novel coronavirus-infected pneumonia in Wuhan, China. *JAMA* 2020;323(March (11)):1061–9.
- Zhao J, Jiang F, Zhong L, Sun J, Ding J. Age patterns and transmission characteristics of hand, foot and mouth disease in China. *BMC Infect Dis* 2016;16(November (1)):691.